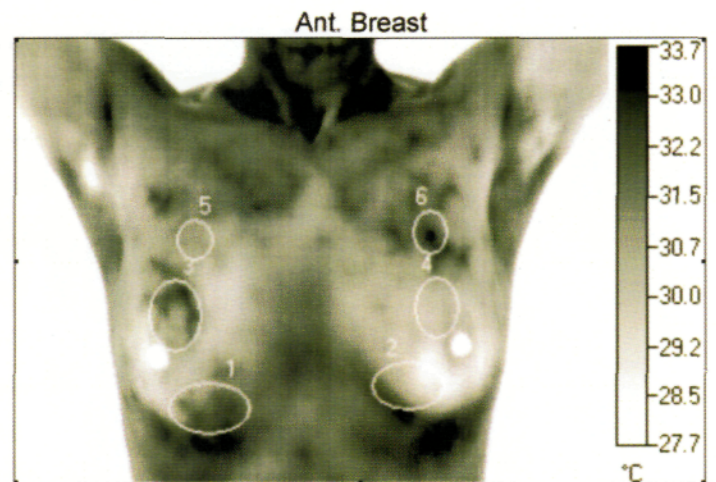
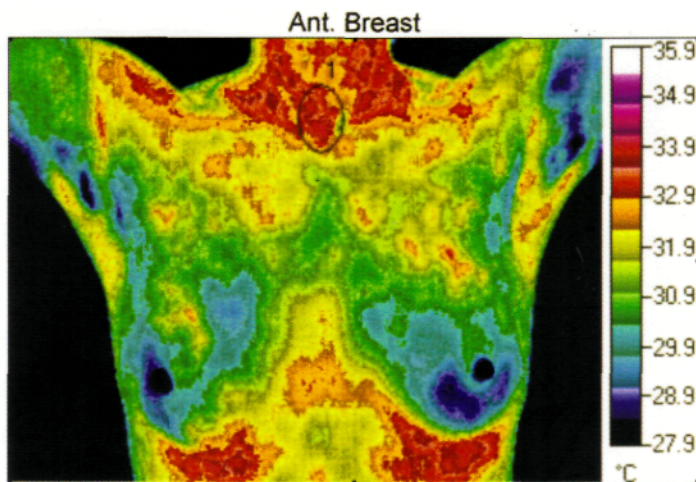


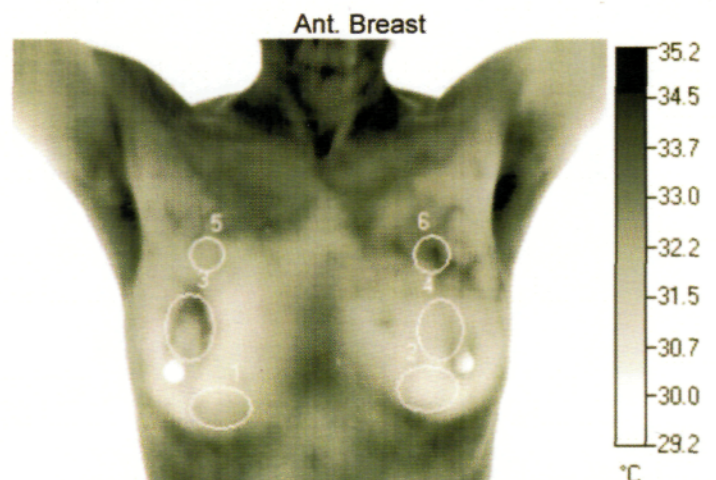
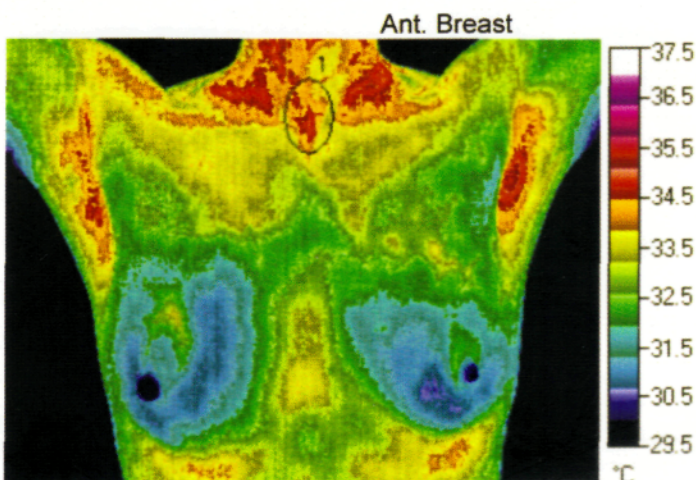
Thermal Imaging of Abnormal Breast Activity



	1	2	3	4	5	6
Type	Circle	Circle	Circle	Circle	Circle	Circle
Maximum	33.1°C	33.2°C	32.9°C	31.1°C	31.2°C	33.3°C
Average	31.7°C	30.3°C	31.1°C	30.0°C	30.7°C	31.9°C
Minimum	29.5°C	28.3°C	28.8°C	29.4°C	30.1°C	30.9°C
Delta Avg		1.4°C		1.1°C		-1.2°C
Std. Dev	0.731	1.343	0.727	0.312	0.189	0.581

September 2009

Client's thermal images display hyperthermic thyroid, hormonal imbalance, lymphatic congestion to the right lower medial breast, abnormal vascular growth to upper right breast with a Delta Average of 1.1 and abnormal vascular growth to left upper outer breast with a Delta Average of 1.2.



	1	2	3	4	5	6
Type	Circle	Circle	Circle	Circle	Circle	Circle
Maximum	32.7°C	32.6°C	33.7°C	32.6°C	32.6°C	34.2°C
Average	31.6°C	31.1°C	32.2°C	31.6°C	32.1°C	33.0°C
Minimum	30.5°C	30.4°C	30.9°C	30.6°C	31.7°C	31.9°C
Delta Avg		0.5°C		0.6°C		-0.9°C
Std. Dev	0.492	0.443	0.577	0.358	0.157	0.439

December 2009

Client's three month follow-up shows over all improvement to the breast tissue. No hormonal signatures, lymphatic congestion to the right lower medial breast is clear; showing no signs of congested lymph, the vascular growth to both the upper left and right breast has significantly improved: closer temperature differentials with lower Delta Averages and the vascular patterns are dissipating.

Client followed Teresa Lopez's protocols faithfully for three months to achieve these results. The BioMat is one key therapy through her healing and improvements.